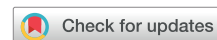

Retrograde administration of ultrasound-guided endovenous microfoam chemical ablation for the treatment of superficial venous insufficiency



Steven T. Deak, MD, PhD, FACS, *Somerset, NJ*

ABSTRACT

Objective: This study measured patient outcomes among symptomatic patients with superficial chronic venous insufficiency who were treated with retrograde ultrasound-guided polidocanol microfoam 1% in a community setting.

Methods: Between March 2015 and June 2017, 250 symptomatic patients with C2-C6 chronic venous insufficiency received polidocanol microfoam 1% and were followed for 16 ± 7 months. Sixteen of the 250 patients (6.4%) had skin ulcers, and 56 (22.4%) were treated previously with thermal or surgical interventions. All patients underwent a duplex ultrasound venous incompetence study to map perforators and veins to be treated. Incompetent veins were accessed with a micropuncture needle distal to the midhigh perforator, approximately 10 cm above the knee fold. The leg was then elevated 45°. Under ultrasound guidance, the incompetent greater saphenous vein was closed with polidocanol microfoam 1%. A second injection was administered through the same catheter directing the microfoam to flow in a retrograde fashion through the incompetent venous valves to the ankle.

Results: All patients completed the initial treatment; 55 (22.0%) required planned secondary treatment during the follow-up period for residual venous reflux in the below-knee greater saphenous vein. Complete elimination of venous valvular reflux and symptom improvement was documented in 236 patients (94.4%). Minor adverse events included asymptomatic deep vein thrombi ($n = 2$), common femoral vein thrombus extension ($n = 1$), and superficial venous thrombi ($n = 4$). Of the 16 patients with skin ulcers, 10 were C6 patients and 80% experienced wound closure within 4 weeks of treatment.

Conclusions: Retrograde administration of polidocanol microfoam 1% is a safe and effective treatment with important clinical benefit for superficial venous insufficiency in community practice. (*J Vasc Surg: Venous and Lym Dis* 2018;6:477-84.)

Keywords: Polidocanol; Venous insufficiency; Venous leg ulcer

Chronic venous insufficiency (CVI) is a common and debilitating disease that affects 20% to 30% of the adult population worldwide.¹ Symptoms documented include persistent heaviness, achiness, swelling, throbbing, and itchiness, skin/soft tissue damage, and pain. In the most severe cases, venous ulceration results in substantial quality of life impairment, missed workdays, and increased healthcare costs.²⁻⁶ Left untreated, disease progression with accompanying increases in symptom severity occurs in approximately 58% of the patients; 4.5% of patients with CVI progress annually.⁷

Established treatment options for CVI include conservative treatment, surgery, stab phlebectomy, sclerotherapy with physician-compounded sclerosing agents, endovenous laser ablation, radiofrequency ablation, mechanochemical endovenous ablation, or cyanoacrylate glue

occlusion. Although effective, these treatment options have limited application in patients with complicated and tortuous anatomy or advanced disease. Consequently, many providers will schedule several treatment sessions that combine the use of a catheter-based treatment intervention with a surgical approach (eg, stab phlebectomy or sclerotherapy). Invasive surgical interventions are accompanied by the obvious trauma associated with incisions and soft tissue damage, and tumescent, thermal-based procedures may be associated with a risk of paresthesia when ablation is performed below the knee.⁸

Ultrasound-guided endovenous chemical ablation is a less invasive, nonthermal, nontumescent technique that uses U.S. Food and Drug Administration-approved polidocanol microfoam 1% under ultrasound guidance to injure the endothelial cell layer within the venous lumen.⁹ Polidocanol microfoam 1% has a low nitrogen content (<0.8%) to reduce the risk of neurologic complications, because nitrogen is not absorbed within the body and can lead to gas embolism. Additionally, it is manufactured with a guaranteed uniform bubble size, distribution, and density to increase efficacy by ensuring optimal contact with the vascular lumen.¹⁰ The 1:7 liquid:gas ratio, and the higher O₂ versus CO₂ content increases foam stability, blood displacement, and the time that the foam remains

From the Deak Vein NJ Clinic.

Author conflict of interest: none.

Correspondence: Steven T. Deak, MD, PhD, FACS, Deak Vein NJ Clinic, 37 Clyde Rd #102, Somerset, NJ 08873 (e-mail: stdeak@gmail.com).

The editors and reviewers of this article have no relevant financial relationships to disclose per the Journal policy that requires reviewers to decline review of any manuscript for which they may have a conflict of interest.

2213-333X

Copyright © 2018 by the Society for Vascular Surgery. Published by Elsevier Inc. <https://doi.org/10.1016/j.jvs.2018.03.015>

in the vessel. It has also been shown to be safe and effective for all patients with C2 to C6 CVI disease, vein diameters up to 25.9 mm, or tortuous veins.^{3,4,11} In contrast, physician-compounded foam has a questionable safety profile owing to the high nitrogen content and variable bubble size,¹²⁻¹⁷ and its efficacy has been shown to be inconsistent and inferior in comparison to the other modalities available for venous ablation.¹⁸⁻²⁰

Although the safety and efficacy of polidocanol microfoam 1% has been established in phase III clinical trials, the medical literature lacks evidence regarding its safety and effectiveness in a community practice.

METHODS

This research was exempt under Saint Peters University Institutional Review Board Guidelines because it was a retrospective chart review of deidentified data conducted by the investigator, who was the sole provider of medical care to all participants. All patients signed an informed consent. Primarily, the decision to treat patients was based on the presence of symptoms (Fig 1), pathologic reflux, and failure to experience improvements in symptoms after 3 months of standard compression therapy. Patient selection for type of treatment was based on anatomic factors and treatment history. Patients with tortuous veins that were not accessible with a catheter were ideal candidates for treatment. Also, if patients had incompetent veins below the knee or a history of a previous vein ablation procedure that may have left fibrous or scar tissue in the vessel, they were selected for treatment. All patients signed an informed consent before treatment with polidocanol microfoam 1%.

Patients were first evaluated in the standing position using a duplex ultrasound technique. Mapping was performed, including the measurement and marking of major tributaries into the great saphenous vein (GSV) as

ARTICLE HIGHLIGHTS

- **Type of Research:** Single-center retrospective cohort study
- **Take Home Message:** Analysis of ultrasound-guided 1% polidocanol microfoam saphenous ablations in 250 patients with C2 to C6 disease revealed complete elimination of valvular reflux and early symptom improvement in 94.4%. Adverse events included asymptomatic deep vein thrombi in two patients, common femoral vein thrombus extension in one patient, and four cases of superficial thrombophlebitis.
- **Recommendation:** Polidocanol microfoam ablation of the incompetent great saphenous veins in patients with C2 to C6 disease with chronic venous disease is safe and effective.

well as locations of perforating veins (both competent and incompetent). The skin was then anesthetized with 1% lidocaine at the puncture site overlying the GSV and a 2-mm incision was made at the skin puncture site. Under ultrasound guidance, the vein to be treated was punctured with a micropuncture needle followed by passage of a 0.018 guidewire through the puncture needle. A 5F catheter was inserted over the guidewire, the wire and dilator were removed and the sheath was flushed with a saline solution.

The lower extremity was then placed on a foam wedge at an angle of 45° to empty the varicose veins of blood. Five milliliters of U.S. Food and Drug Administration-approved polidocanol microfoam 1% (Varithena; BTG Interventional Medicine, West Conshohocken, Pa) was generated from the can into a sterile, silicone-free syringe and injected into the vascular catheter at a rate of

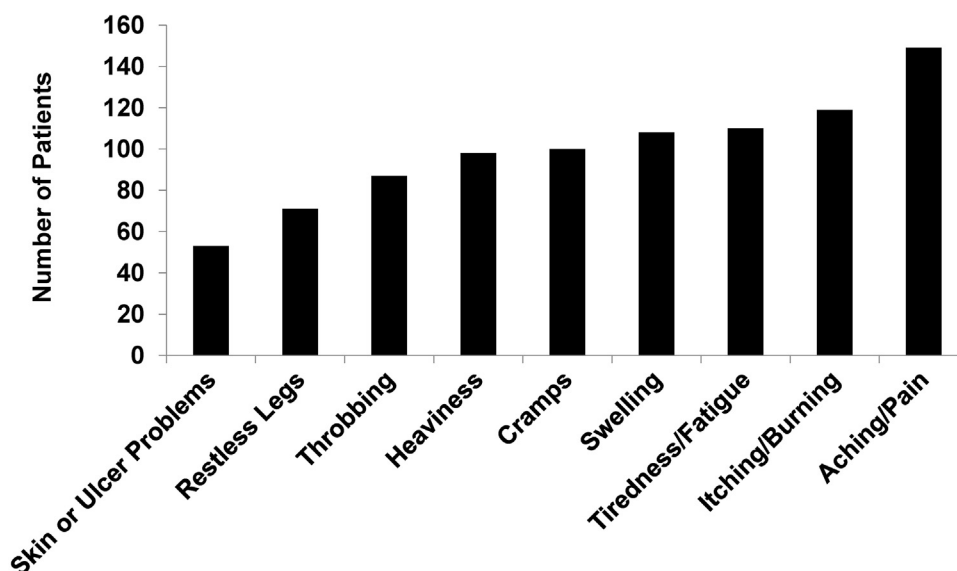


Fig 1. Patient symptoms pretreatment.

0.5 to 1.0 mL/second under ultrasound observation. Once the microfoam arrived within 3 to 5 cm of the sapheno-femoral junction, the GSV was compressed for 2 to 3 minutes to limit the flow of microfoam into the common femoral vein.

After spasm of the GSV was confirmed in the treated segment of the vein, additional 4- to 5-mL injections of microfoam were delivered through the same vascular catheter. The GSV was then compressed to encourage the microfoam to flow retrograde into the calf. This approach, along with compression of the incompetent perforating vein, helps to reduce the volume of microfoam entering the perforator in the proximal calf near the GSV. Treated veins were consistently observed for 3 to 5 minutes to confirm spasm. To minimize the risk of deep venous thrombosis, the patient was instructed to dorsiflex the foot for approximately 30 seconds to activate the calf pump and close patent perforators after each injection.

The lower extremity was kept elevated at 45° as dressings were applied to prevent blood from entering the treated vein. While the leg remained elevated, short stretch wraps were placed on the leg from the distal foot up to the groin. The wrap was secured in place and a 20- to 30-mm Hg compression thigh length elastic support hose was placed on the patient. The leg was then placed back into a horizontal position and the patient instructed to ambulate for 10 minutes under supervision to monitor for potential anaphylaxis as a result of polidocanol allergy. All patients were then discharged home with instructions to ambulate for at least 10 minutes several times per day.

Patients returned to the office 5 to 7 days after treatment for a follow-up visit. Duplex ultrasound analysis was performed to identify areas of patency, document reflux, and locate any potential deep vein thrombi. Owing to the extensive nature of chronic venous disease in many patients, and the guidance of the U.S. Food and Drug Administration that no more than 15 mL of endovenous microfoam be used per treatment, some patients required additional treatment sessions to eliminate reflux or areas of patency. These treatment sessions occurred during follow-up visits. Patients with active ulceration returned for follow-up until the wound closed, and closure was documented at two separate visits at least 2 weeks apart.

RESULTS

Patients. The average age for the 250 patients studied was 54.7 years (range, 30-95 years), 15% were at least 65 years old, and 68% were female. As indicated in the prescribing information, patients were excluded from treatment if they had an allergy to polidocanol, pregnancy, or acute DVT. All patients experienced symptoms that included heaviness, achiness, swelling, throbbing, or itching that prompted them to seek treatment. Sixteen

patients (6.4%) had active ulcers ($n = 10$) or spontaneous bleeding ($n = 6$) (Table; Fig 2). Fifty-six patients (22.4%) had been treated previously with other thermal or surgical interventions. Fourteen percent of the patients ($n = 36$) had prior endovenous laser ablation, 7% of the patients ($n = 17$) underwent surgical stripping and ligation, and 1.2% of the patients ($n = 3$) had previous stab phlebectomy. In patients with active ulcers, previous treatments that failed to heal the ulcer included surgical vein procedures, thermal ablation, phlebectomy, Unna boots, and compression therapy.

Duplex ultrasound assessments. Mean reflux time in the GSV among patients was 2.24 ± 1.12 seconds. Mean vein diameter was 8.0 ± 2.5 mm. In this cohort, the smallest vein diameter treated was 4.1 mm and the largest vein diameter treated was 18.7 mm (Fig 3). Elimination of reflux was documented in 94.4% of patients (236 of 250) after all planned treatments were completed.

Polidocanol microfoam 1% treatment. Mean polidocanol microfoam volume administered during the initial procedure was 9.5 ± 2.5 mL and was successful in 78.0% of patients ($n = 195$). In the remaining 55 patients, a second treatment of endovenous polidocanol microfoam 1% was used to eliminate reflux in the below-knee segments that continued to reflux and cause symptoms. Subsequent procedures were performed between 5 days and 2 years after the initial procedure (10 ± 18 weeks). Most procedures were performed at 1 week after treatment or up to 80 weeks after treatment, contributing to the large SD.

Patient satisfaction. The majority of patients (94.4%) had relief of their symptoms. These patients did not return to the clinic during the follow-up period (16 ± 7 months) owing to a return or worsening of symptoms. Patients with extremely tortuous and superficial veins had more pronounced improvements (Figs 3 and 4).

Ulcerations. The Table includes single patient data for the patients in this cohort with ulcerations and bleeding. Six patients had previous invasive venous procedures including ligation and stripping ($n = 2$), endothermal ablation ($n = 3$), and phlebectomy ($n = 1$). Prior treatments ranged from 1 to 10 years prior. In these patients, the mean ulcer size was 2.7 ± 1.5 cm at the largest diameter with the largest ulcer measuring 6 cm in diameter before polidocanol microfoam 1% treatment. The mean vein size was 8.6 ± 3.1 mm, with the largest vein measuring 15.1 mm in diameter. Average reflux time was 1.29 ± 0.80 seconds, and the average amount of polidocanol microfoam used was 10.4 ± 2.8 mL. During the first month of posttreatment follow-up visits, 80% of the ulcers had healed (8 of 10; $P = .01$) with a mean healing time of 20.7 ± 6.7 days (Table; Fig 5). There were no reports of recurrence in these eight patients.

Table. Demographics for patients treated for ulcer or bleeding with polidocanol microfoam 1%

Age, years	Sex	Ulcer size, cm	Ulcer Classification	Vein treated	Vein size, mm	Vein reflux, seconds	Prior adjunct treatment	Polidocanol used, mL	Result
95	F	3	Nonhealing ulcer	Left GSV, accessory	6.4	0.84	Ligation, stripping of left GSV, and 136 Unna boots	5	Healed: 31 days
65	M	1.5	Nonhealing ulcer	Right GSV	10.6	1.59		8	Healed: 20 days
59	M	4.3	Nonhealing ulcer	Right GSV	7.4	0.5		10	Not healed
46	M	2.5	Nonhealing ulcer	Right GSV	12	1.19		10	Healed: 21 days
39	F	2	Nonhealing ulcer	Right GSV (below knee)	10.3	1.40	EVRA and PCF	14	Healed: 12 days
38	M	1.5	Nonhealing ulcer	Right GSV	15.1	3.47	EVRA	15	Healed: 20 days
65	F	3	Nonhealing ulcer	Right GSV	6.2	1.03		9	Healed: 27 days
66	M	2.5	Nonhealing ulcer	Right GSV	6.9	1.26	Phlebectomy and 3 Unna boots	9	Healed: 14 days
49	M	6	Nonhealing ulcer	Left GSV	8.1	1.07	11 Unna boots	13	Not healed
49	M	0.5	Nonhealing ulcer	Left GSV	4.6	1.37	PCF and 25 Unna boots	11	Partial healing
72	F	—	Bleeding	Right GSV	5.6	0.50		13	Closed GSV, no bleeding
57	M	—	Bleeding	Left GSV	10.6	2.83		9	Closed GSV, no bleeding
39	M	—	Bleeding	Right GSV	6.4	2.03	RFA, EVLA (right GSV)	13	Closed GSV, no bleeding
39	F	—	Bleeding	Right GSV	7.4	1.00		9	Closed GSV, no bleeding
63	M	—	Bleeding	Right GSV	8.2	2.53	5 Unna boots	9.5	Closed GSV, no bleeding
56	F	—	Bleeding	Left GSV	9.9	2.44	PCF	15	Closed GSV, no bleeding

EVLA, Endovenous laser ablation; EVRA, endovenous radiofrequency ablation; GSV, great saphenous vein; PCF, physician-compounded foam; RFA, radiofrequency ablation.

Complications. Adverse events documented included two asymptomatic DVTs identified during routine Duplex ultrasound surveillance during follow-up visits. One DVT was in the midfemoral vein at the site of the midhigh perforator. The patient was treated for 3 months with anticoagulants. The second patient had a DVT in the proximal femoral vein and was also treated for

3 months with anticoagulants. Patients were instructed to walk daily and report any symptoms in the affected limb. DVTs resolved without issue. One patient experienced a common femoral vein thrombus extension, a nonocclusive small thrombus that extends from the GSV to the common femoral vein. The patient was asymptomatic and monitored until the common femoral vein

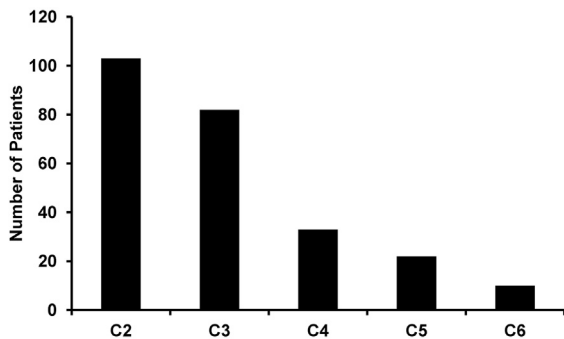


Fig 2. Clinical, etiologic, anatomic and pathophysiologic (CEAP) distribution. Forty-two percent of the patients were classified as CEAP 2 (42%), and 58% were classified as CEAP 3-6.

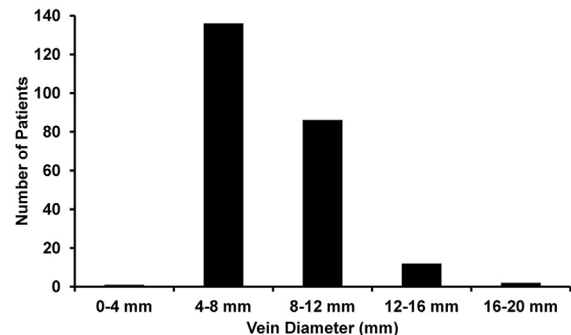
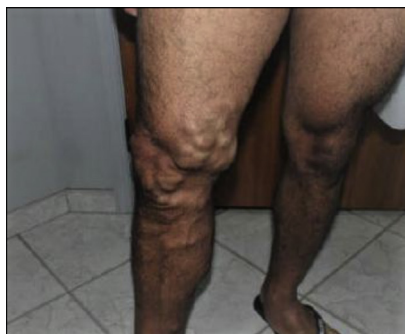
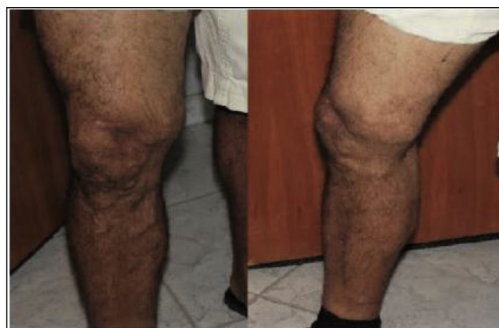
Fig 3. Vein diameter (millimeters). Sixteen percent of the patients had vein diameters of greater than 10 mm.



**GSV Reflux 1.8 seconds
GSV Diameter 16.1 mm**



**Two weeks post-treatment,
8.1 mL total treatment
volume**

Fig 4. Varicose veins before and after treatment with polidocanol microfoam 1%. GSV, Great saphenous vein.

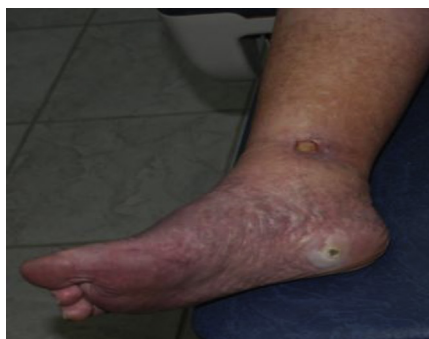thrombus extension resolved. Four patients experienced superficial venous thrombi, accompanied by minor discomfort. Patients were instructed to take anti-inflammatories and keep compresses on the affected vein until symptoms resolved. Fourteen patients (5.6%) were considered technical failures because duplex ultrasound assessment did not identify complete elimination of reflux or the GSV could not be accessed, mainly in the early part of the study. Of these patients considered technical failures, eight patients were treated in the early part of the series and six failures were due to vein spasm or vein thrombosis when obtaining access. The mean diameter of the veins in the technical failure group was 8.0 ± 2.9 mm.

DISCUSSION

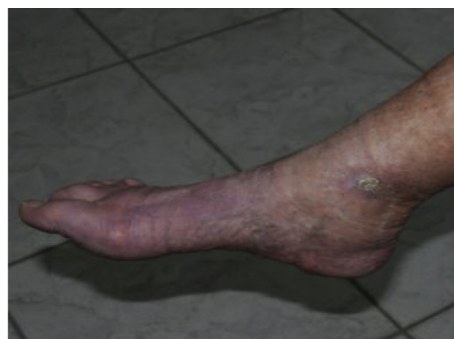This retrospective, noncontrolled, medical chart review of 250 patients was performed to determine if

polidocanol microfoam 1% is safe and efficacious in eliminating or minimizing symptoms of CVI in a community practice. We report that 94.4% of patients treated had complete elimination of pathologic reflux in superficial treated segments. In the 10 patients with C6 disease who presented to the clinic with chronic wounds of varying severity and duration, wound healing was observed within a few weeks of treatment. Together, these outcomes highlight the integral role that polidocanol microfoam 1% plays in a large practice when catheter-based technologies may not be suitable for all patients.

Patient selection for polidocanol microfoam 1% treatment in this practice was driven by two primary factors: venous anatomy and previous treatment. In regard to venous anatomy, although there is an established role for phlebectomy or surgery in patients with tortuous anatomy, ulcerations, or below-knee varicosities, the limitations associated with these interventions make them less favorable options in practice. With the emergence



Pre-treatment



Three weeks post-treatment

Fig 5. A C6 ulcer before and after treatment with polidocanol microfoam 1%.

of newer nonthermal and noncatheter technologies, there is compelling rationale to incorporate these treatment options into practice. The outcomes observed in this patient cohort, particularly those related to relief of symptoms and ulcer healing, suggest that polidocanol microfoam 1% may have comparable safety and efficacy to other thermal and surgical-based interventions used in practice.²¹

The second factor driving treatment of patients with polidocanol microfoam 1% was whether or not patients had been treated before for symptoms and reflux in the GSV or accessory veins. Nearly 25% of the patients profiled in this case series had a previous intervention to eliminate reflux in an affected segment or accessory tributary of the GSV, yet returned to the clinic for treatment owing to the return of symptoms and/or for recanalization of the treated vein. These patients are usually not candidates for catheter-based technologies because scarring in the lumen makes passing a catheter through the vein challenging. Even when able to pass a catheter through the lumen, higher energy requirements are needed owing to the thickened vein wall, with a greater risk of thermal injury.

Of note in this patient cohort was that vein diameters ranged from 4.1 to 18.7 mm and the frequency of success among patients was not correlated with vein diameter. This is in contrast to previous reports indicating that one of the greatest predictors of recanalization with treatments other than polidocanol microfoam 1% is vein diameter.²² For this reason, many widely accepted treatment interventions are not indicated or selected for use in veins that are larger than 12 to 15 mm.²² Physician-compounded foam is typically not durable enough to treat veins with larger diameters, because its physical makeup prevents uniform contact with the vein wall.²³ Other nonthermal devices have shown limited efficacy in veins larger than 6 mm,²⁴ and others have not been tested in veins greater than 12 mm, contributing to their limited application in patients with large veins.²⁵ In contrast, the data from phase III clinical trials for polidocanol microfoam 1% U.S. Food and Drug Administration approval established that symptom resolution was similar across vein diameters, with some patients presenting with veins greater than 25 mm in diameter.^{4,11} In part, these data encouraged the use of polidocanol microfoam 1% in this patient cohort with large GSV diameters. Sixteen percent of this patient population had veins greater than 10 mm.

The percent of patients in this cohort who experienced ulcer healing after treatment with polidocanol microfoam 1% was significant. Although the ESCHAR trial (Comparison of surgery and compression with compression alone in chronic venous ulceration) demonstrated a decrease in ulcer recurrence rates with saphenous reflux elimination, there was no improvement in the acceleration of wound healing.²⁶ In recent single-arm prospective

study, the elimination of saphenous vein reflux has been associated with accelerated wound healing.²⁷ Despite the growing body of evidence that elimination of saphenous reflux is beneficial in patients with venous ulceration, these investigations do not directly address the effects of treating the vasculature underneath the ulcer bed. Owing to the complications associated with using most venous ablation modalities in vascular beds that lie beneath lower extremity ulcerations, foam is increasingly becoming a first-line treatment for patients with venous leg ulcers. The retrograde administration of polidocanol microfoam 1% from a single remote access site allows for the improved delivery of the drug into the ulcer bed. Herein we document successful healing of recalcitrant ulcers in 80% of patients ($P = .01$) who were treated with polidocanol microfoam 1%. Justification to use polidocanol microfoam 1% as opposed to physician-compounded foam is based on the excellent margin of safety demonstrated in phase III pivotal trials in more than 1300 patients.^{3,11,28} In that cohort, no pulmonary emboli, neurologic events, or deaths were recorded.

This case series does have its limitations. Primarily, the retrospective nature of this medical chart review eliminated the methodologic rigor that would be applied to a prospective, clinical trial. Consequently, there is a lack of control over the timing of the intervention, data collection, and patient behaviors after the procedure. Second, owing to the increased use of polidocanol microfoam 1% in this practice, there was no comparator dataset with which to equate these data. However, because of the restrictions in treatment options available for the cohort outlined in this series, the anatomic and pathologic profile of the patients would be different in a comparator dataset confounding the outcomes. Specifically, the cohort would be composed of patients with straight GSVs requiring ablation for the first time. Additionally, because this was a retrospective chart review, we did not collect disease-specific quality of life or venous clinical severity scores on all patients. Because the time point of patient follow-up was variable, it prevented us from drawing any firm conclusions regarding treatment-related changes in the venous clinical severity score. Also, although the initial goal of this study was to characterize the safety and efficacy of treatment in a community setting, there is significant interest in long-term data (eg, >3 years) involving patient outcomes. A controlled, prospective study is certainly warranted so that these data are available in the medical literature for reference. Despite these limitations, all patients reported for follow-up visits over the course of the chart review period (16 ± 7 months).

No major complications were reported in this cohort. Seven patients (2.8%) experienced minor complications after treatment with polidocanol microfoam 1%, including asymptomatic DVT, common femoral vein

thrombus extension, and superficial venous thrombi. These side effects have been reported with other ablative methods in similar cohorts, in some cases with greater frequency.^{29,30} Because severe allergic reactions have been reported after the administration of liquid polidocanol, including anaphylactic reactions, the package insert indicates that all patients should be observed in the office for at least 10 minutes after injection and providers should be prepared to treat anaphylaxis appropriately. We did not need to treat any patients for allergy in this study.

A small percentage of the patients (5.6%) were considered technical failures owing to the inability to cannulate the vein, or to completely abolish pathologic reflux in the symptomatic vein. Factors such as obesity, inadequate compression, calf muscle pump dysfunction, or deep vein obstruction may contribute to the persistent superficial incompetence in these patients. However, this rate of technical failure is in line with other venous ablative methods.²⁰

CONCLUSIONS

In this case series of 250 patients with C2 to C6 disease, polidocanol microfoam 1% use resulted in successful improvement in symptoms and healing in patients with ulceration. Because these patients were not candidates for a catheter-based therapy such as endothermal ablation, or surgical interventions such as stab phlebectomy, this case series highlights the successful use of an alternative nonthermal treatment option in a large cohort of patients, at a single center, with 100% initial follow-up from 1 month to 2 years. Overall, these data illustrate comparable safety and efficacy to other thermal and surgical-based interventions used in practice.

REFERENCES

1. Onida S, Davies AH. Predicted burden of venous disease. *Phlebology* 2016;31(1 Suppl):74-9.
2. Marston WA. Evaluation of varicose veins: what do the clinical signs and symptoms reveal about the underlying disease and need for intervention? *Semin Vasc Surg* 2010;23:78-84.
3. Todd KL 3rd, Wright DI, Group V-I. The VANISH-2 study: a randomized, blinded, multicenter study to evaluate the efficacy and safety of polidocanol endovenous microfoam 0.5% and 1.0% compared with placebo for the treatment of saphenofemoral junction incompetence. *Phlebology* 2014;29:608-18.
4. King JT, O'Byrne M, Vasquez M, Wright D, Group V-I. Treatment of truncal incompetence and varicose veins with a single administration of a new polidocanol endovenous microfoam preparation improves symptoms and appearance. *Eur J Vasc Endovasc Surg* 2015;50:784-93.
5. Paty J, Turner-Bowker DM, Elash CA, Wright D. The VVSymQ(R) instrument: use of a new patient-reported outcome measure for assessment of varicose vein symptoms. *Phlebology* 2016;31:481-8.
6. Rice JB, Desai U, Cummings AK, Birnbaum HG, Skornicki M, Parsons N. Burden of venous leg ulcers in the United States. *J Med Econ* 2014;17:347-56.
7. Lee AJ, Robertson LA, Boghossian SM, Allan PL, Ruckley CV, Fowkes FG, et al. Progression of varicose veins and chronic venous insufficiency in the general population in the Edinburgh Vein Study. *J Vasc Surg Venous Lymphat Disord* 2015;3:18-26.
8. Weiss RA, Weiss MA. Controlled radiofrequency endovenous occlusion using a unique radiofrequency catheter under duplex guidance to eliminate saphenous varicose vein reflux: a 2-year follow-up. *Dermatol Surg* 2002;28:38-42.
9. Whiteley MS, Dos Santos SJ, Fernandez-Hart TJ, Lee CT, Li JM. Media damage following detergent sclerotherapy appears to be secondary to the induction of inflammation and apoptosis: an immunohistochemical study elucidating previous histological observations. *Eur J Vasc Endovasc Surg* 2016;51:421-8.
10. Carugo D, Ankrett DN, Zhao X, Zhang X, Hill M, O'Byrne V, et al. Benefits of polidocanol endovenous microfoam (Varithena(R)) compared with physician-compounded foams. *Phlebology* 2016;31:283-95.
11. Todd KL 3rd, Wright DI, Group V-I. Durability of treatment effect with polidocanol endovenous microfoam on varicose vein symptoms and appearance (VANISH-2). *J Vasc Surg Venous Lymphat Disord* 2015;3:258-64.e1.
12. Cavezzi A, Parsi K. Complications of foam sclerotherapy. *Phlebology* 2012;(Suppl 1):46-51.
13. Kim M, Niroumandpour M, Poustinchian B. Transient ischemic attack after foam sclerotherapy in a woman with a patent foramen ovale. *J Am Osteopath Assoc* 2016;116:320-3.
14. Ma RW, Pilotelle A, Paraskevas P, Parsi K. Three cases of stroke following peripheral venous interventions. *Phlebology* 2011;26:280-4.
15. Parsi K. Paradoxical embolism, stroke and sclerotherapy. *Phlebology* 2012;27:147-67.
16. Sarvananthan T, Shepherd AC, Willenberg T, Davies AH. Complications of sclerotherapy for varicose veins. *J Vasc Surg* 2012;55:243-51.
17. Wright DD, Gibson KD, Barclay J, Razumovsky A, Rush J, McCollum CN. High prevalence of right-to-left shunt in patients with symptomatic great saphenous incompetence and varicose veins. *J Vasc Surg* 2010;51:104-7.
18. Lawaetz M, Serup J, Lawaetz B, Bjoern L, Blemings A, Eklof B. Comparison of endovenous ablation techniques, foam sclerotherapy and surgical stripping for great saphenous varicose veins. Extended 5-year follow-up of a RCT. *Int Angiol* 2017;36:281-8.
19. Rasmussen L, Lawaetz M, Serup J, Bjoern L, Vennits B, Blemings A, et al. Randomized clinical trial comparing endovenous laser ablation, radiofrequency ablation, foam sclerotherapy, and surgical stripping for great saphenous varicose veins with 3-year follow-up. *J Vasc Surg Venous Lymphat Disord* 2013;1:349-56.
20. Brittenden J, Cotton SC, Elders A, Ramsay CR, Norrie J, Burr J, et al. A randomized trial comparing treatments for varicose veins. *N Engl J Med* 2014;371:1218-27.
21. Puggioni A, Kalra M, Carmo M, Mozes G, Gloviczki P. Endovenous laser therapy and radiofrequency ablation of the great saphenous vein: analysis of early efficacy and complications. *J Vasc Surg* 2005;42:488-93.
22. Van der Velden SK, Lawaetz M, De Maeseneer MG, Hollestein L, Nijsten T, van den Bos RR, et al. Predictors of recanalization of the great saphenous vein in randomized controlled trials 1 year after endovenous thermal ablation. *Eur J Vasc Endovasc Surg* 2016;52:234-41.
23. Shadid N, Nelemans P, Lawson J, Sommer A. Predictors of recurrence of great saphenous vein reflux following treatment with ultrasound-guided foam sclerotherapy. *Phlebology* 2015;30:194-9.

24. Chan YC, Law Y, Cheung GC, Cheng SW. Predictors of recanalization for incompetent great saphenous veins treated with cyanoacrylate glue. *J Vasc Interv Radiol* 2017;28:665-71.
25. Kim PS, Bishawi M, Draughn D, Boter M, Gould C, Koziarski J, et al. Mechanochemical ablation for symptomatic great saphenous vein reflux: a two-year follow-up. *Phlebology* 2017;32:43-8.
26. Gohel MS, Barwell JR, Taylor M, Chant T, Foy C, Earnshaw JJ, et al. Long term results of compression therapy alone versus compression plus surgery in chronic venous ulceration (ESCHAR): randomised controlled trial. *BMJ* 2007;335:83.
27. Harlander-Locke M, Lawrence PF, Alktaifi A, Jimenez JC, Rigberg D, DeRubertis B. The impact of ablation of incompetent superficial and perforator veins on ulcer healing rates. *J Vasc Surg* 2012;55:458-64.
28. Todd KL 3rd, Wright D, Orfe E. The durability of polidocanol endovenous microfoam treatment effect on varicose vein symptoms and appearance in patients with saphenofemoral junction incompetence: one-year results from the VANISH-2 study. *J Vasc Surg Venous Lymphat Disord* 2014;2:112.
29. Tang TY, Kam JW, Gaunt ME. ClariVein(R) - early results from a large single-centre series of mechanochemical endovenous ablation for varicose veins. *Phlebology* 2017;32:6-12.
30. Morrison N, Gibson K, Vasquez M, Weiss R, Cher D, Madsen M, et al. VeClose trial 12-month outcomes of cyanoacrylate closure versus radiofrequency ablation for incompetent great saphenous veins. *J Vasc Surg Venous Lymphat Disord* 2017;5:321-30.

Submitted Dec 1, 2017; accepted Mar 8, 2018.